

See discussions, stats, and author profiles for this publication at: <https://www.researchgate.net/publication/297229165>

# Evaluating the Accuracy of the "Breastlight" as a Screening Tool for Breast Cancer in Iraq

Article · January 2014

---

CITATION

1

READS

67

7 authors, including:



**Nada Alwan**

University of Baghdad

75 PUBLICATIONS 239 CITATIONS

SEE PROFILE

Some of the authors of this publication are also working on these related projects:



National Strategy of Lung Cancer Control [View project](#)



Molecular genetic analysis in breast cancer [View project](#)

All content following this page was uploaded by [Nada Alwan](#) on 07 March 2016.

The user has requested enhancement of the downloaded file.



ISSN NO. 2320-5407

Journal homepage: <http://www.journalijar.com>

INTERNATIONAL JOURNAL  
OF ADVANCED RESEARCH

## RESEARCH ARTICLE

## Evaluating the Accuracy of the "Breastlight" as a Screening Tool for Breast Cancer in Iraq

Nada A. S. Al-Alwan (MD, PhD Path)<sup>1</sup>, Israa Hussain (MD, PhD.)<sup>2</sup>, Heba Abdul Wahid (MD)<sup>2</sup>, Inaam Aziz (MD, D.Rad.)<sup>3</sup>, Aqeel Shakir (PhD Surg)<sup>2</sup>, Wigdan Hamza (MD)<sup>3</sup>, Maha Gasim<sup>3</sup>.

1. Prof. of Pathology, Director (National Cancer Research Centre, Baghdad University).

2. College of Medicine, Baghdad University.

3. Main Referral Training Center for Early Detection of Breast Tumours, Medical City Hospital..

### Manuscript Info

#### Manuscript History:

Received: 25 August 2014

Final Accepted: 29 September 2014

Published Online: October 2014

#### Key words:

Breast light, Screening, Breast Cancer, Accuracy, False Positive, Specificity, Iraq.

#### \*Corresponding Author

Nada A. S. Al-Alwan (MD, PhD Path)

### Abstract

Breast cancer is the most common malignancy in Iraq and is the leading cause of death among women. The poor survival reflects the limited public awareness among the general population. The Hope light, a domestic breast checker, has been designed as an aid for breast cancer awareness

The present study was carried on a randomly selected sample of 150 female patients who visited the Main Training and Research Centre for early detection of breast cancer in Baghdad. Patients were examined with the Hope light device; the findings were compared with the results of clinical breast examination, mammography, ultrasound, and fine needle aspiration cytology (FNAC) as the gold standard for sensitivity and specificity.

Breast cancer was detected in 24% of the cases. Among those, the Hope light demonstrated positive findings in 80.56% (**True Positive**). On the other hand, in 19.44%, the device failed to reveal any positive finding (**False Negative**). FNAC revealed benign pathology in 73.72%. Of those, negative findings were recorded using the device in 53.47%, (**True Negative**), while in the remaining 46.53% the device yielded **False positive** findings.

**In conclusion**, although the accuracy of the Hope Light in detecting palpable malignant breast lumps was significant, nevertheless, the observed high false positive detection rate and the significantly low specificity in excluding malignancy preclude its use as a screening tool for breast cancer.

Copy Right, IJAR, 2014.. All rights reserved

## Introduction

Breast cancer is the most common cancer among women in both the developed and the developing world. Higher rates of survival from the disease have been reported in high-income regions of the world, nevertheless, survival remains low in middle-and low-income countries where the risk continues to increase (1, 2). The variation in survival outcomes is mostly due to differences in the level of awareness, availability and access to early detection techniques and treatment modalities (3).

Mammography screening programs are not feasible in developing countries due to cost effective measures, limited health-care resources and inadequate infrastructure; when present, they are used for diagnostic purposes (2, 4). Evidence based research does not support the efficacy of screening by clinical breast examination (CBE) or breast self examination (BSE) in reducing mortality from breast cancer in women (3, 5).

The Breastlight, or the so called domestic Breast Checker was designed to be utilized by women at home as an aid for breast awareness. It is a handheld device that transluminates the breast with a red light, at a wavelength of 617 nm, that is absorbed by haemoglobin yielding dark shadows in areas of high vascularity (including malignancy). The manufactures of the device claim that its results have been extremely favorable in women that have large lumpy breasts (6). On the other hand, the Breast light has been ruled as 'misleading' by other investigators (7).

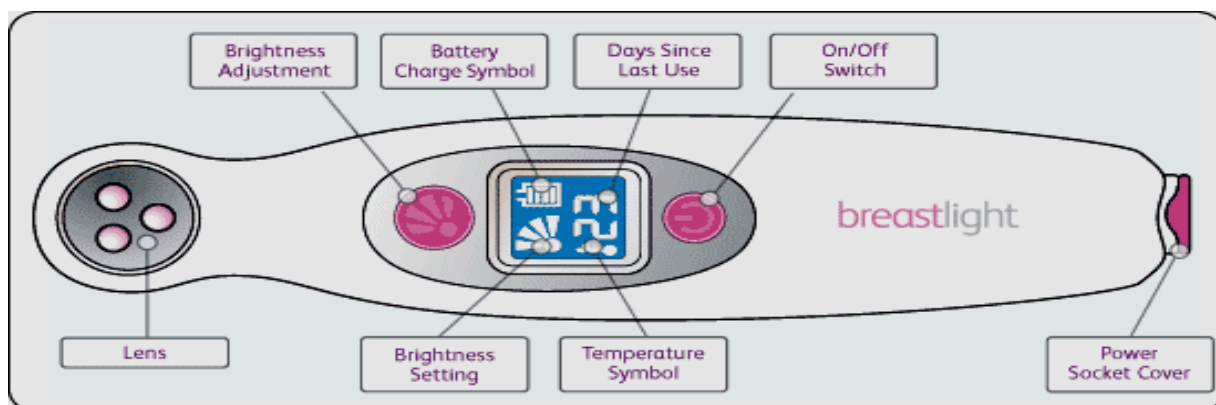
As breast cancer is the most common type of malignancy among the Iraqi population in general (8), a national program for early detection and down staging of that disease has been initiated in collaboration with WHO since 2001. Within the Main Referral Center for Early Detection of Breast Tumours in Baghdad the "Triple Assessment Technique" is routinely practiced for assessing abnormalities in patients presenting with breast complaints (9). In 2012, a locally manufactured version of the Breastlight, the "Hope Light" device was introduced in the center to evaluate its accuracy in diagnosing breast cancer; by comparing its findings with those obtained from using imaging and biopsy techniques.

### **Patients and Methods:**

The present study was carried on a sample of randomly selected 150 female patients who visited the "Main Referral Training Centre for Early Detection of Breast Tumors" of the Medical City Teaching Hospital and the "Iraqi National Cancer Research Center" of Baghdad University during a five month period (May 2012 – September 2012). The main complaints included palpable breast lumps, nipple discharge, nipple retraction, skin changes and mastalgia. For each patient all relevant information included within the official file sheet questionnaire were recorded (i.e., demographic, clinical, diagnostic imaging and laboratory data).

### **Examination by the "Hope Light" Device:**

Before being subjected to the standard Triple Assessment techniques, consenting patients were examined with the Hope light device, by a trained technician supervised by the pathologist, within a dark room (figure 1). Both breasts were examined without being aware which the cause of concern was. The device was turned on and pressed tightly against the skin all over the breast tissue.



**Figure ( 1 ): The Display Panel in the Hope Light Device.**

Figure (1) reveals the four symbols on the display panel:

- 1- The **brightness setting** indicator showing the selected level of brightness.
- 2- The **battery charge** symbol.
- 3- The **temperature indicator** which signals overheating conditions.
- 4- The **days since last used** indicator as a reminder.

The mode of action of the Hope light device is based upon the fact that when light is transmitted through the breast tissues in a fully darkened room, it will be absorbed by hemoglobin in the blood vessels that appear as dark lines. The normal image revealed the superficial blood vessels, the nipple and the areola as dark shadows against a mainly red background (Figure 2). Owing to the angiogenesis in the malignant lumps, they should appear by that device as dense dark opacities within a bright red background (Figure 3).

In all patients, examination with the Hope Light device was carried out before introducing the needle by fine needle aspiration (FNA) as the latter might cause hematoma that leads to false positive results with the light device. During the examination, any dark spots or shadows were recorded.

### Triple Assessment Examination:

All patients were then evaluated using the standard routine triple assessment examination, The findings of the Hope light examination were compared with the results of CBE, mammography, ultrasound, and finally, fine needle aspiration cytology (FNAC) as the gold standard for the sensitivity and specificity.

Ultrasonographic examination was performed for all patients by using Acuson X300 ultrasound machine (Siemens) with high frequency linear array 7.5-10 MHz transducer/ Mammographic screening was applied on women over 40 years utilizing Digital GE Mammography equipments. The recorded breast lesions were categorized according to BIRADS lexicon into groups according to the degree of suspicion; where groups (1-3) favour benign nature, group (4) reflects suspicious changes and group (5) indicates highly suggestive of malignancy.

FNA was carried out by competent pathologists utilizing disposable 10 ml syringes attached to 22- or 23-gauge needles. The aspirated material was immediately fixed in 99% ethanol for at least 20 minutes and then examined cytologically after staining by Papanicolaou. Breast lesions were categorized pathologically according to the FNAC findings into benign, atypical or malignant.

When comparing the results of the aforementioned detection procedures, cases diagnosed as BIRAD 4, by the imaging techniques, and atypical, by FNAC, were excluded from the statistical analysis for the tests of accuracy. All positive results obtained by the triple assessment tests were confirmed by histopathology.

## Results:

**Table (1): Age Distribution of the Study Sample According to the Pathological Diagnosis.**

Age Group	Benign cases		Malignant Cases		Total	
	No	%*	No	%**	No	%***
10-19	5	4.39	0	0	5	3.33
20-29	25	21.93	0	0	25	16.67
30-39	33	28.95	4	11.11	37	24.67
40-49	30	26.32	14	38.89	44	29.33
50-59	17	14.91	9	25.00	26	17.33
60-69	4	3.51	9	25.00	13	8.67
Total	114	100	36	100	150	100

\*Percentage of Benign Cases

\*\*Percentage of Malignant Cases

\*\*\*Percentage of Total Cases

Table (1) shows the distribution of the study sample according to the age of the patients correlated with the pathological diagnoses of the breast lesions. Among young women under the age of 30 years (n= 30), all breast complaints were diagnosed as benign by FNAC. On the other hand, the peak frequency of breast cancer occurred in women aged 40-49 years (38.8%).

**Table (2): Distribution of the Studied Sample According to the Cytopathological Diagnosis.**

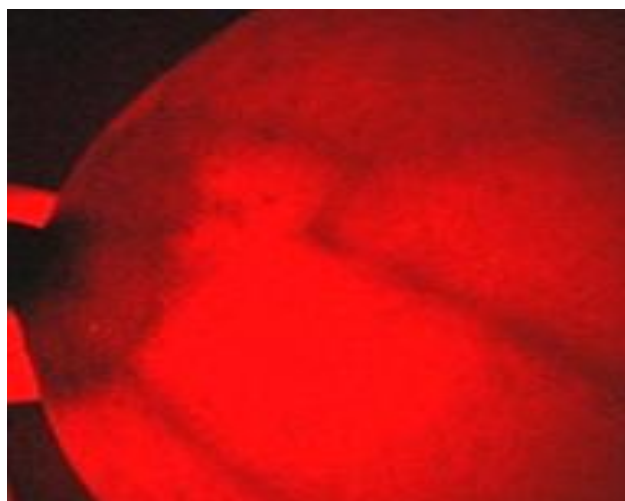
Pathological Diagnosis of cases according to FNAC	Total number	Percentage of Total
Fibrocystic changes	40	26.7
Breast Carcinoma	36	24.0
Fibroadenoma	18	12.0
Inflammatory associated conditions	11	7.3
Duct Ectasia	4	2.7
Fat Necrosis	3	2.0
Intraductal Papilloma	4	2.7
Galactocele	2	1.3
Lactating Adenoma	2	1.3
Lipoma	1	0.7
Benign Non Specific Changes	16	10.7
Atypical*	13	8.7
<b>Total</b>	<b>150</b>	<b>100</b>

\*8 cases were associated with Fibrocystic Changes, 2 with Fibroadenoma, 2 with Mastitis and one with Intraductal Papilloma.

Table (2) demonstrates the cytopathological diagnoses in 150 patients according to FNAC results. Breast carcinoma was detected in 36 patients (24%); all of the cases were confirmed histologically – given that all patients in whom the triple assessment technique was positive were subjected to mastectomy.

The most specific cytopathological diagnosis in the remaining 137 benign cases was Fibrocystic Changes (26.7% of total) followed by Fibroadenoma (12% ), while benign non-specific cellular changes were observed in 10.7%. Atypical cytological changes were displayed in FNA specimens belonging to 13 patients who were not subjected to Hope Light examination (8 cases were associated with Fibrocystic Changes, two with Fibroadenoma, two with Mastitis and one with Intraductal Papilloma). The latter entity was excluded from the evaluation.

**Figure (2): Examination of the right breast of a 34 old lady by the Hope Light Device revealing normal breast findings: the superficial blood vessels, the nipple and the areola appearing as dark shadows against a mainly red background.**



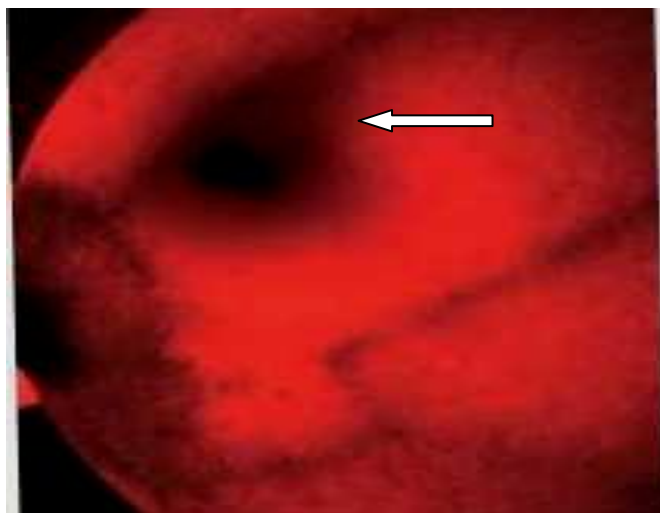


Figure (3): Findings in the left breast of a 42 year old woman examined by the Hope Light: a malignant lump (arrow) appearing as a dense dark opacity within a bright red background in view of the remarkable angiogenesis.

Table (3): Correlation of the Findings of the Hope Light Device with the Cytopathologic Diagnosis (in Benign and Malignant breast lesions).

Final Pathological Diagnosis	Hope light (-ve) Findings No (%)	Hope Light (+ve) Findings			Total examined No (%)
		Faint Dark Shadow No (%)	Dense Dark Shadow No (%)	Total No. of MAMO +ve No (%)	
+ve (Malignant)	7/36 (19.44%) <b>FALSE -ve</b>	18/29 (62.07%)	11/29 (37.93%)	29/36 (80.56%) <b>TRUE +ve</b>	36/137 (26.28%)
-ve (Benign)	54/101 (53.47%) <b>TRUE -ve</b>	20/47 (42.55%)	27/47 (57.45%)	47/101 (46.53%) <b>FALSE +ve</b>	101/137 (73.72%)
Total	61/137 (44.53%)	38/137 (27.74%)	38/137 (27.74%)	76/137 (55.47%)	137

$$\text{Sensitivity: } \frac{\text{(True + ve)}}{\text{(True + ve) + (False -ve)}} = \frac{29}{29 + 7} = 80.56\%$$

$$\text{Specificity: } \frac{\text{(True - ve)}}{\text{(True - ve) + (False + ve)}} = \frac{54}{54 + 47} = 53.47\%$$

The correlation of the findings of the Hope Light in Benign and Malignant breast lesions is displayed in Table (3). Overall, the breasts of 137 (91.33%) patients were evaluated by the Hope Light device. Breast cancer was diagnosed by FNAC and later on confirmed by histopathology in all the 36 detected malignant cases [26.28%]. Among those, the Breast light demonstrated positive findings in 29/137 cases (80.56%), i.e., signifying **True Positive** results by the device. On the other hand, in 7/36 cases (19.44%), the device failed to reveal any positive finding, i.e., **yielding False Negative** results. Among the latter group, three patients were premenopausal in age, five had malignant tumor components measuring less than 2 cm in diameter and two had very small breasts. .

FNAC revealed benign pathology in 101/137 cases (73.72%) of the study sample. Of those, negative findings were recorded using the device in 54/101 (53.47%), i.e., **True Negative** results, while in the remaining 47/101 (46.53%) the device yielded positive findings, i.e., **False Positive** results. It is worthwhile mentioning that within the latter group, 57.5% of the observed opacities were rather dark. The pathological causes of False Positive Hope Light findings in benign breast lesions are illustrated in Table 4.

**Table (4): Causes of False (+ve) Hope Light Results in the Benign Group.**

Pathological Diagnosis of Benin Cases (according to FNAC)	Positive by Hope Light		Total
	No	%	
Fibrocystic Changes	18 45		40
Abscess	4 80		5
Fibroadenoma	9 50		18
Mastitis	5 83.3		6
Duct Ectasia	1 25		4
Intraductal Papilloma	3 75		4
Fat Necrosis	2 66.7		3
Benign Non Specific	4 25		16
Lactating Adenoma	1 50		2
Galactocoel	0 0		2
Lipoma	0 0		1
<b>Total</b>	47 46.5		101

The most common cause was inflammatory associated conditions (83.3% and 80% of cases were diagnosed as mastitis and abscess respectively). That was followed by Fat Necrosis (66.7%), Fibroadenomas and Lactating Adenomas (50% each). In 18 out of 40 cases (45%) diagnosed as Fibrocystic Changes the Hope Light revealed dark shadows on examination; in 7 of those (38.9%), the aspirated fluid was blood-tinged.

**Table (5): Accurate Detection Rates of the Hope Light Device in Palpable versus Non-Palpable Breast Lesions.**

<b>CBE Findings / Pathological Result #</b>	<b>Negative by Hope Light</b>		<b>Positive by Hope Light</b>		<b>Total</b>
	<b>No</b>	<b>%</b>	<b>No</b>	<b>%</b>	
<b>Non-Palpable Lesion / Benign #</b>	17	73.91	6	26.09	23
<b>Non-Palpable Lesion / Malignant #</b>	0	0	0	0	0
<b>Palpable Lump / Benign #</b>	37	47.44	41	52.56	78
<b>Palpable Lump / Malignant #</b>	7	19.44 <b>(False -ve)</b>	29	80.56 <b>(True +ve)</b>	36
<b>Total</b>	61		76		137

Table (5) illustrates that out of 23 non palpable benign breast lesions, six cases (26.09%) revealed faint dark shadows by the Hope Light device, i.e., False Positive reactions (two cases were diagnosed cytologically as mastitis, two as fibroadenosis and two as non-specific benign). Among the remaining 78 benign palpable breast lumps, False Positive dark spots were demonstrated in 41 cases (52.56%).

Regarding breast carcinoma, where all the examined lumps among the 36 patients were palpable, dark areas favoring True Positive detection rates of the device was displayed in 29 patients (80.56%). Interestingly, within the latter category, the observed shadows were dense dark in 38% only of the examined cases versus 62% where the breast tissues revealed faint dark opacities (Table 3). False Negative detection rates were observed in 7/36 (19.44%). The accuracy of the detection rate of the Hope Light in palpable lumps was significant ( $p < 0.05$ ).

## **Discussion:**

Breast cancer, one of the major threats to Iraqi women health, accounts for more than one third of the registered female cancers and is the leading cause of death from malignancies among affected women (1, 9). Within the last two decades, there has been an obvious increase in the incidence rates of the disease; with a considerable proportion of patients presenting at younger age groups and at advanced stages yielding high mortality incidence ratios (1, 9-10). The poor survival reflects the limited awareness among Iraqi women, the weak referral system and other socioeconomic barriers (5, 11, 12).

In the current study, 38.9% of the diagnosed patients were in their forties, where the peak frequency of the disease was observed. That trend of the disease to affect middle aged generations has been consistently highlighted in other Iraqi records (8-10) and many reports from the region (4, 13, 14); probably attributable to the younger demographic profile of the Arab population.

An earlier study conducted in the same center on 721 Iraqi patients seeking advice for apparent breast lumps, demonstrated that 14.3% were diagnosed with breast cancer; one third of whom presented in the fifth decade of life. Although the lump was detected by the patient herself in 90% of the cases, only one third of those sought medical advice within the first month (9). Another survey applied on a sample of educated women, affiliated to two prominent universities in Iraq, reported that of the 91% who have heard about BSE only 48% actually practiced the technique (11). The findings of these studies justify urging efforts for establishing comprehensive nationwide breast cancer control programs in the country focusing mainly on early detection and promoting public awareness.

In the current study, the most frequent registered pathological diagnosis among symptomatic women was Fibrocystic changes (26.7%) followed by mammary carcinoma (24%) and Fibroadenoma (12%). These lesions are often recorded as the most common causes for women seeking advice in breast clinics (15).



The Hope light is a transilluminator electronic device that uses low-intensity emissions of visible light which is transmitted through the breast tissues to visualize abnormalities. The ancient well known fact that breast cancer could be demonstrated by transmission of light through the tissues (16) is based upon the resulting optical images associated with angiogenesis; where red blood cells strongly absorb light at about 550 nm (the absorption bands of oxyhaemoglobin) (17). The Breast Light device was introduced in the United States, Canada and the United Kingdom since 2006 (6, 7). The manufacturer companies claimed that the device was well accepted by women and the medical community, serving as a strong tool in the breast cancer awareness campaigns and that its favorable results could be superior to those obtained from CBE in detecting some breast lesions (6).

Among our patients, there was no transmission of light through the breasts in two women who had small breast sizes; where Ultrasound examination revealed benign lesions. On the other hand, better results were obtained when examining patients with large breasts. That was in accordance with the observations noted by other investigators who pointed out that the results of the Breast light were encouraging in patients who had large, lumpy fibrous breasts who find BSE difficult (18).

The registered "Sensitivity" for the Hope Light device in detecting breast cancer was 80.6%; False Negative results being noted in 19.4%. False Positive findings (i.e., benign lesions reflecting dark shadows), on the other hand, were observed in 47 out of 101 benign breast lesions that were diagnosed by the imaging techniques and confirmed pathologically; thus yielding a "Specificity" equivalent to 53.47%. False positive results were reported in patients with blood filled cysts, haemorrhagic lesions and inflammatory associated conditions; including mammary mastitis, abscesses, fibrocystic changes, intraductal papilloma and fibroadenoma. Similar findings were observed by other investigators who reported that some benign conditions might be expected to reflect positive results by the Breast light due to the presence of residual bleeding or suppurative inflammation (19).

In initial published clinical trials from the University of Aberdeen (20), where 178 patients were investigated by the prototype version of the breast illumination method, 69 of the 95 confirmed carcinomas were detected yielding a sensitivity of 73% which was raised to 83% in cancers over 2 cm. in diameter and in patients over 50 years. In the remaining 83 patients, benign lesions were correctly demonstrated by the device in 68 cases (82%). In an earlier study, the Edinburgh Royal Infirmary Hospital (19) included a total of 129 patients; of those 74 had confirmed breast cancer, 70 of which were accurately detected by using the breast illumination technique (95%). The same device showed negative reactions in 50 out of the remaining 55 benign cases.

A prospective study performed one year later on 285 women, presenting with symptomatic breast diseases in an outpatient clinic in Nottingham, documented that the light scanning detected 87.8% of the histologically confirmed breast cancers (21). That figure was higher than that displayed by the same authors when using mammography. It was then hypothesized that if such device was used by women at home on a monthly basis, then fewer women should present with large advanced cancers requiring mastectomy. A more sophisticated Breast Checker based on optical and ultrasound Doppler technology was later invented in 1989 for use in primary health care centers (22).

In 2009, a trial comprising 300 patients conducted at Sunderland City Hospital in Malaysia (23) reported that the Breast light detected 12 of 18 malignant tumors presenting a sensitivity of 67%, while 240 of 282 benign breast lesions were correctly identified as negative; recording a specificity of 85%. The local distributor of the product there announced that the device might be an ideal alternative in young premenopausal women who are not candidates for the screening programs and in those who refuse mammography. An earlier trial carried out in the rural areas of Ghana, by a charity which used the same device as part of their screening process, reported a success rate of 96% in diagnosing breast cancer (18). The investigators claimed that the torch could even spot tiny lumps as small as 7 mm in diameter which were not palpated by CBE.

In the current study, the encountered "False Negative" detection rates of the Hope Light obviously carry the risks of missed diagnosis and delayed management. On the other hand, the demonstrated high "False Positive" results could be accompanied by anxiety and phobia often secondary to over detection of non-specific benign lesions. Other hazards reported in the literature associated with using such devices include the risks of electrical shock and thermal or eye injuries (24).

D'Orsi, a recognized expert in the field of breast imaging and mammography, investigated 3000 women in an NIH-funded grant to evaluate the efficacy of breast transillumination. The investigator failed to find any case of carcinoma that was positive by light scanning alone and negative by CBE and/or mammography (25). In fact, based on the

recommendation of the Obstetrics and Gynecology Devices Panel, the FDA published in 1995 a final rule that placed breast transilluminators in the Class III medical device category; displaying that there were no published evidence based clinical data to highlight the effectiveness and safety of such devices (24, 26). That regulation was confirmed in 2010 and 2012 by the FDA consensus panel which requested premarket approval applications with supporting data from clinical trials to shed more light on the technology. It is worthwhile mentioning that most medical imaging devices including digital mammography are considered as examples of Class II devices, while Class III are defined as products that present "a potential, unreasonable risk of illness or injury" (24).

Coinciding with our concerns, Health Canada warned about the misleading advertising of the product and its potential risks. Federal authorities declared that the Breast Light was not authorized to be used effectively as a screening tool or breast cancer; advising Canada Border Services Agency to stop any importation of the device and instructing the pharmacies to stop promoting the product. On the same line, Cancer Research in Britain called on the major pharmacy chain "Boots" to stop stocking the Breast Light (7, 28). By that time the product was already sold in 12 countries all over the world (6, 27, 28).

Nevertheless, the manufacturers continued to promote their products in developing countries (6, 18, 23) reaching the Middle East (28). Recently, Lotus Middle East Pharma and its partner Brighl Medical Future Supplies have launched the Breast Light in the UAE (28) and are currently paving their ways through the markets of neighboring countries in the region.

### Conclusions:

Although the accuracy of the Hope Light in detecting malignant breast lumps in this study was significant, yet, its high false positive detection rate and the significantly low specificity of the device in excluding malignancy preclude its use as a screening tool for breast cancer in Iraq.

### Acknowledgement

The authors would like to acknowledge the support of the manufacturers of the "Hope Light" device; namely Mr. Thamir Hussain, Mr., Raad and Mrs Samar. Azeez from the Ministry of Science and Technology in Iraq.

### References:

1. International Agency for Research on Cancer (2010). *Globocan 2008. World Cancer Statistics*. Lyon, IARC Press. Available at: <http://globocan.iarc.fr/factsheets/populations/factsheet.asp?uno=900>.
2. Anderson BO et al. (2008). Guideline implementation for breast healthcare in low-income and middle-income countries: overview of the Breast Health Global Initiative Global Summit 2007 *Cancer*, 113, 2221–43.
3. Sankar R, Alwan N & Lynn DI (2013). How Can We Improve Survival from Breast Cancer in Developing Countries?. *Future Medicine, Breast Cancer Management*, 2 (3): 179-183.
4. WHO/EMRO (2010). *Towards a Strategy for Cancer Control in the Eastern Mediterranean Region*, 1st ed. Cairo, *World Health Organization Regional Office for the Eastern Mediterranean*
5. Von Karsa et al (2014). *World Cancer Report 2013. Implementation of Cancer Screening: The Global Outlook*. IARC, WHO
6. Breast Screening, Self Breast Exam, Breast Check with Breastlight last accessed 17 May 2014.
7. Breastlight is Not Authorized for Use as a Screening Device for the Detection of Breast Cancer, health Canada 2010. Last accessed 19 May 2014.
8. Iraqi Cancer Board. *Results of the Iraqi Cancer Registry 2010*. Baghdad, Iraqi Cancer Registry Center, Ministry of Health, 2010.
9. Alwan NAS (2010). Breast Cancer: Demographic Characteristics and Clinico-pathological Presentation of Patients from Iraq. *Eastern Mediterranean Health Journal*, WHO, 16 (11): 1073-1078.
10. Alwan NAS (2000). DNA proliferative index as a marker in Iraqi aneuploid mammary carcinoma. *Eastern Mediterranean Health Journal*, 6:1062–1072.
11. Alwan NAS et al (2012). Knowledge, attitude and practice regarding breast cancer and breast self-examination among a sample of the educated population in Iraq. *Eastern Mediterranean Health Journal* 18 (4):337-45.

12. Alwan NAS et al (2012). Knowledge, Attitudes and Practice towards Breast Cancer and BSE in Kirkuk University, Iraq. *Asian Pacific Journal of Reproduction*, Elsevier, 1 (4): 308-311.
13. Omar S et al. Breast cancer in Egypt (2003). A review of disease presentation and detection strategies. *Eastern Mediterranean Health Journal*, 9 (3):448–461.
14. Rennert G. Breast cancer. In: Freedman L et al (2006). *Cancer incidence in four member counties (Cyprus, Egypt, Israel and Jordan) of the Middle East Cancer Consortium (MECC) compared to SEER*. Bethesda, Maryland, NCI (NIH Pub. No. 06-5873), :73–81.
15. Dixon JM and Thomas J (2012). *Symptoms, Assessment and Guidelines for Referral in ABC of Breast Diseases*. 4<sup>th</sup> ed. BMJ Books.
16. Cutler M (1929). Transillumination as an aid in the diagnosis of breast lesions. *Surg Gynecol Obstet*. 48, 721 – 729.
17. Watmough DJ (1982). Diaphanography; Mechanism responsible for the images. *Acta. Radiologica Oncol*. 21, 11-15.
18. Ghartey F and Watmough D J (2009). Evaluation of a new device Breast light, for use as an adjunct to BSE and Breast Awareness by Mammocare, Ghana. SEMCO, 2nd Annual Breast Cancer Conference, 17- 19 March, Cairo, Egypt.
19. Bundred N., Levack P, Watmough DJ, and Watmough JA (1986). Preliminary results using computerised tele-Diaphanography for the investigation of breast disease. *British J. Hospital Med*. 37, 70-71
20. Brittenden J, Watmough DJ, Heys SD and Eremin O (1995). Preliminary clinical evaluation of a combined optical Doppler ultrasound instrument for the detection of breast cancer. *Brit. J. Radiol*. 68, 1344 – 1348.
21. Dowle CS., Castledine Jennifer, Tew Jennifer et al (1987). An evaluation of transmission spectroscopy (lightscanning) in the diagnosis of symptomatic breast lesions. *Clinical Radiology*. 38, 375 – 377.
22. Watmough DJ (1989). Son et Lumiere; a combined Optical Doppler ultrasound approach to detection of breast cancer. *Radiology*, Jan, 1989.
23. Iwuchukwu O, Dordea M & Keaney N (2010). Analysis of Breast light Findings in Patients with Biopsies. European Institute of Oncology's 12th Breast Cancer Conference, Milan Italy, June 17, 2010. Breast Light. Cancer early warning. Last accessed 17 May 2014.
24. Radiological Devices Panel of the Medical Devices Advisory Committee; Breast Transilluminators , Executive summary (PDF). Notice of Meeting, (April 12<sup>th</sup>, 2012). Food and Drug Administration, HHS.
25. D'Orsi CJ, Smith EH: Double blind study of breast diaphanography. National Institute of Health Grant (N.I.H.) G2736 1984-1989 approved \$195,196/yr RNM# 1RO1CA37970-AIA.
26. FDA panel declines to ease rules on breast transilluminators (2012). Last accessed 20 May 2014.
27. Borland S: Thousands of women misled by £80 torch that claim to detect breast cancer (2012). Breastlight-Thousands-misled-torch-claims...Last accessed: 17 may 2014.
28. Breast Light launched in the Emirates - Lotus Middle East pharma . Last accessed 17 May 2014.